

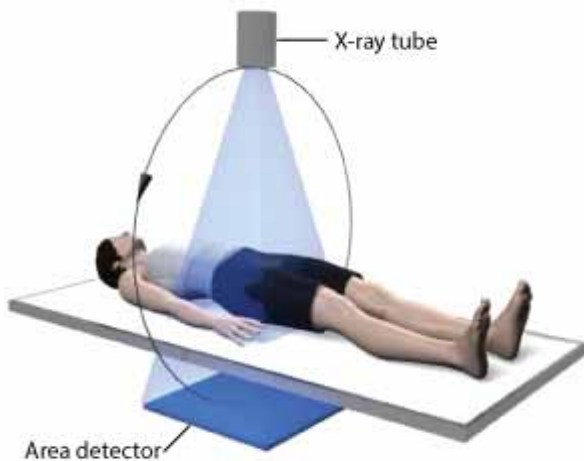
The Advantages of Volumetric Cone Beam Imaging for Orthopaedic Extremity Exams

NOTE: This paper describes the CARESTREAM OnSight 3D Extremity System but was written prior to product availability. The system is now FDA approved and shipping to many countries around the world.

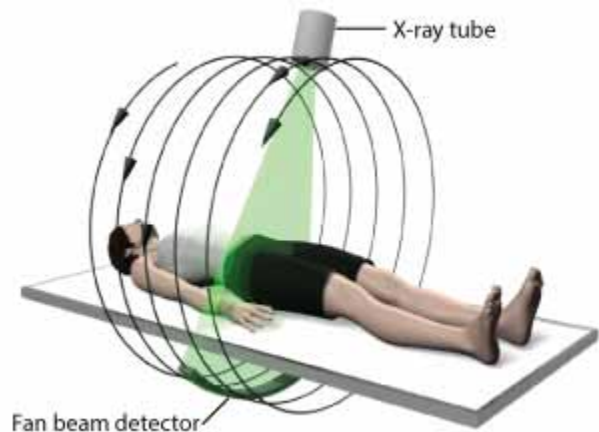
Cone Beam CT Imaging for Extremities

Cone beam computed tomography (CBCT) is a variant of traditional computed tomography (CT) and was first described in the late 1970s. The main difference between the two approaches is the volume of the object that is imaged at one time. In traditional CT, a narrow slice of the patient is imaged with a “fan beam” of X-rays. For an extended volume of the anatomy via CT, the patient must be imaged multiple times through the fan of X-rays as it rotates. In contrast, in CBCT, a large-area detector images an extended volume of the patient in a single rotation. (See Figure 1.)

Figure 1: Comparison between CBCT and traditional CT imaging



CBCT imaging: A large-area detector images an extended volume of the patient in a single rotation.



Traditional CT imaging: A narrow slice of the patient is imaged with a fan beam of X-rays and multiple rotations.

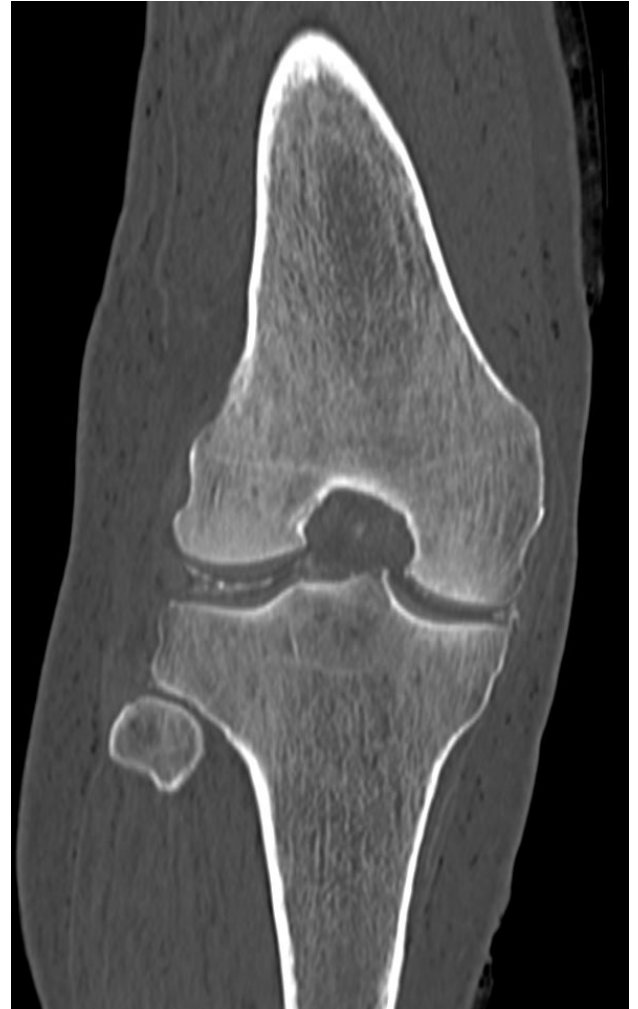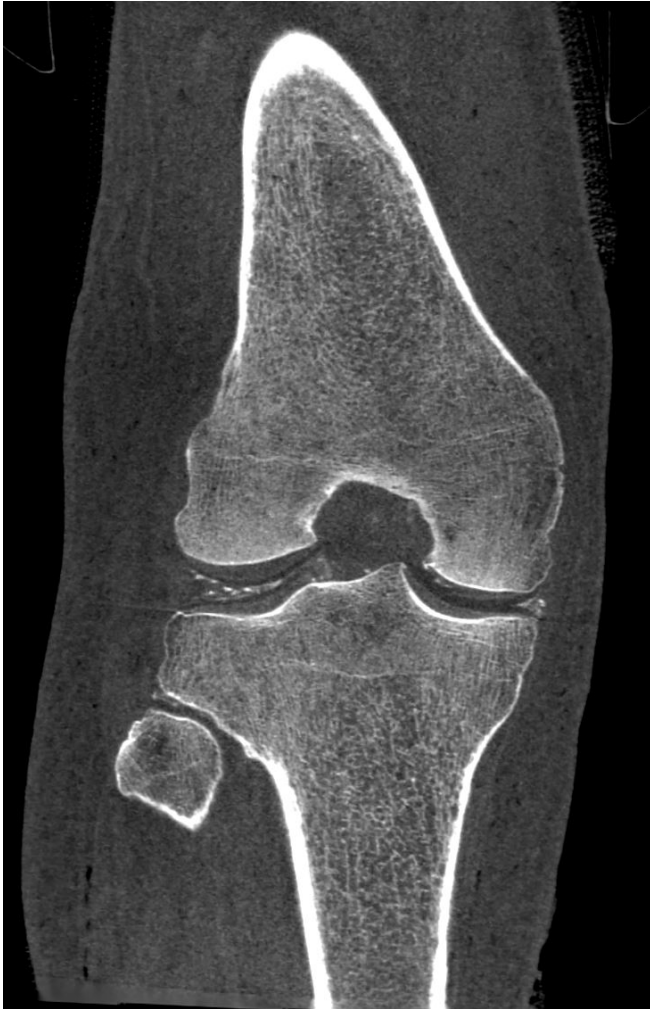In traditional CT reconstruction, the z-axis spatial resolution (the spatial resolution in the direction of motion of the patient) is determined by the speed of translation of the patient through the imaging X-ray fan, coupled with the speed of rotation of the X-ray source around the patient. In this z-axis direction (i.e. the sagittal and coronal planes), the resolution from traditional CT is typically lower than in the perpendicular x-y plane (i.e. the axial plane).

Compare this imaging complexity with CBCT, which offers a more simplified system design. With CBCT, there’s no need for high-speed “slip ring” technology. It also delivers a volumetric reconstruction that has isotropic spatial resolution in all three directions.

Figure 2 shows a scan of a cadaver knee specimen acquired on an Investigational CBCT system under development by Carestream Health, and an image of the same specimen scanned on a standard CT. Note the difference in spatial resolution when using a system specifically designed for extremity imaging.

White Paper | Cone Beam CT (CBCT) Imaging

Figure 2: CBCT image of the cadaver tibio-femoral joint (left) and corresponding MDCT image of the same sample (right)



CBCT has only recently become practical with the introduction of large-area high-speed digital X-ray imagers such as a-Si:H-based flat-panel detectors. The large area, excellent image quality, high resolution and fast readout these new detectors deliver have enabled a range of newly specialized volumetric imaging systems. These have been designed for specific anatomical locations such as dental, ENT and breast imaging, and systems used for image guidance in radiation therapy and intra-operative applications. Carestream is investigating the use of this technology specifically for imaging extremities, and is currently undergoing research with Johns Hopkins University and UBMD Orthopaedics & Sports Medicine.

The generation of volumetric CT images generally has two distinct stages: image acquisition and volume reconstruction.

The Carestream Investigational CBCT system featured in this paper was specifically developed to image extremities (hands/wrists, elbows, knees, feet/ankles), and utilized a number of unique capabilities related to data acquisition and volume reconstruction. This paper highlights some of the distinguishing features of application-specific CBCT imaging systems.

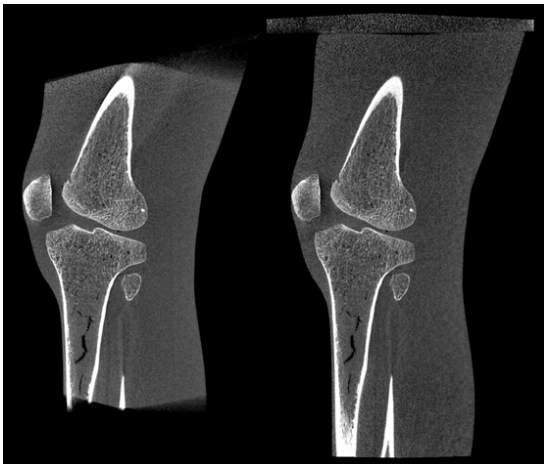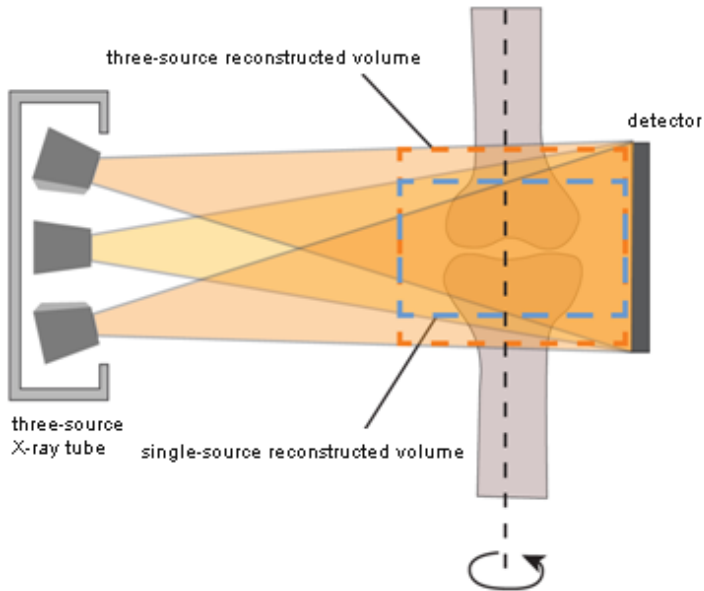
Image Acquisition

The system referenced in this paper utilized a high-performance flat-panel detector and a unique three-source X-ray tube design¹. This detector allowed for the rapid acquisition of X-ray projection, which helped minimize the negative impact of patient motion. The three-source X-ray

White Paper | Cone Beam CT (CBCT) Imaging

tube was designed to reduce the well-known “cone beam” artifact that has traditionally impacted large-volume CBCT reconstructions. This design significantly increased the volume of the reconstruction over what is typically achieved with traditional single-source acquisition. (See Figure 3.)

Figure 3: Three-source vs. one-source configuration

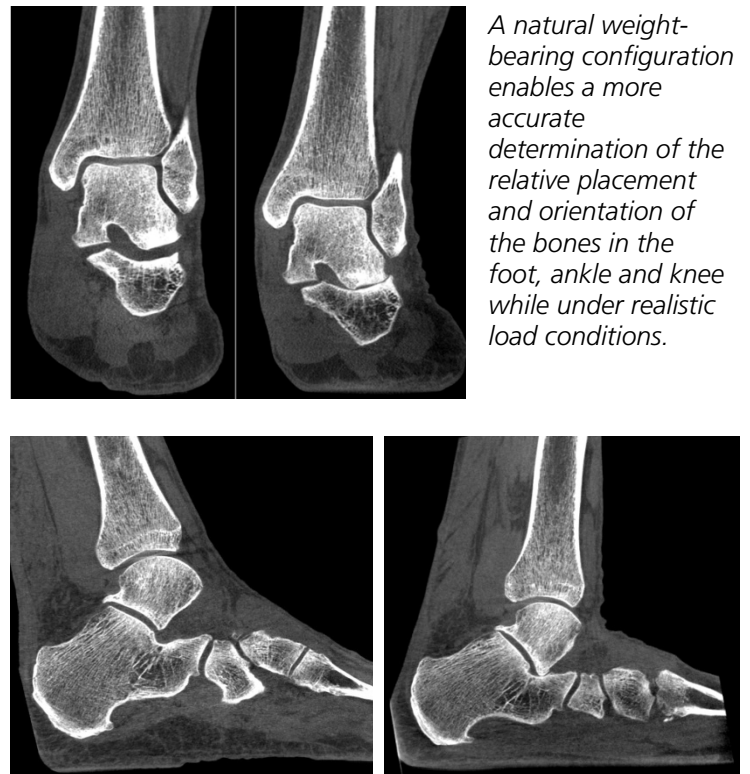

The image above demonstrates the additional Z-Axis reconstruction volume provided by the three-source configuration. (left image: single-source, right image: three-source).

One underappreciated aspect of many CBCT systems is patient workflow. The Carestream prototype system in this paper was designed with patient entry to the imaging volume as one of its most important features. This proprietary “patient entry door” allows easy patient setup for both standing and sitting configurations. In addition, this design allows for imaging of a single knee, foot or ankle in a natural, weight-bearing configuration. The ability to more accurately determine the relative placement and orientation of the bones in the foot, ankle and knee under realistic load conditions is currently under investigation. See Figure 4 for an example of images from the investigational device comparing non-weight-bearing vs. weight-bearing scans of a patient’s ankle to show narrowing of the tibio-talar joint.

Imaging only one extremity at a time also reduces patient exposure below the typical dosages associated with traditional CT systems. (See Figure 5.) Plus, a number of recent publications indicate that the typical range of dose levels used with CBCT systems (CTDIvol in the range ~5-10mGy) are less than dose levels used by CT (CTDIvol~20-50mGy).^{2,3}

Figure 4: Non-weight-bearing vs. weight-bearing foot image



A natural weight-bearing configuration enables a more accurate determination of the relative placement and orientation of the bones in the foot, ankle and knee while under realistic load conditions.

White Paper | Cone Beam CT (CBCT) Imaging

Figure 5 shows two of the stages to position a patient, via the step-in door, for a standing right-knee scan.

Figure 5: Single-leg configuration

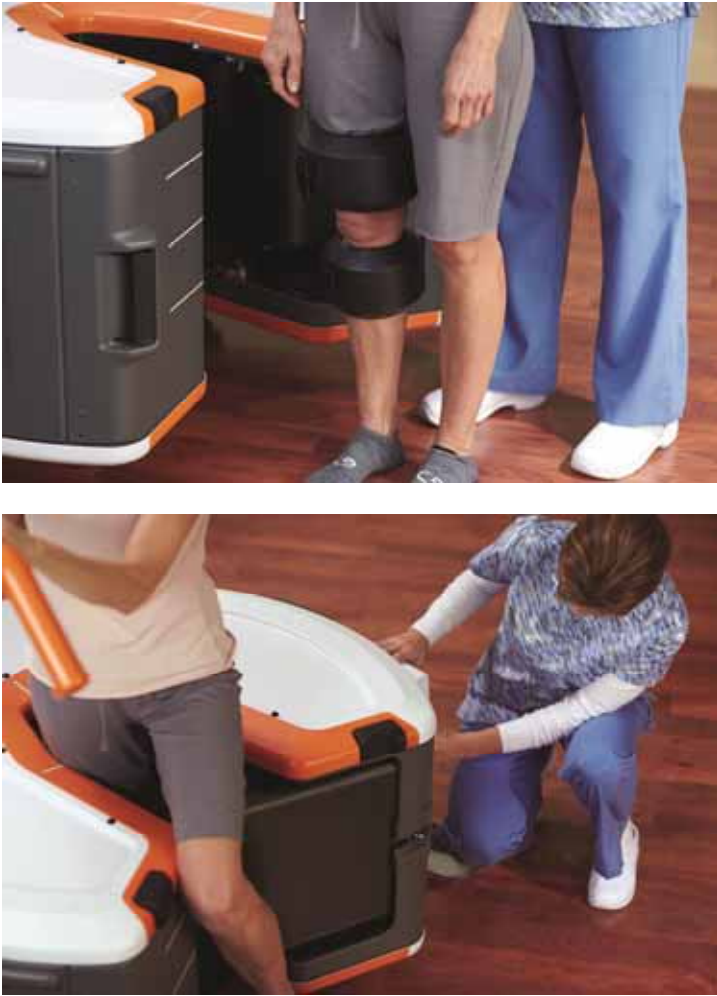
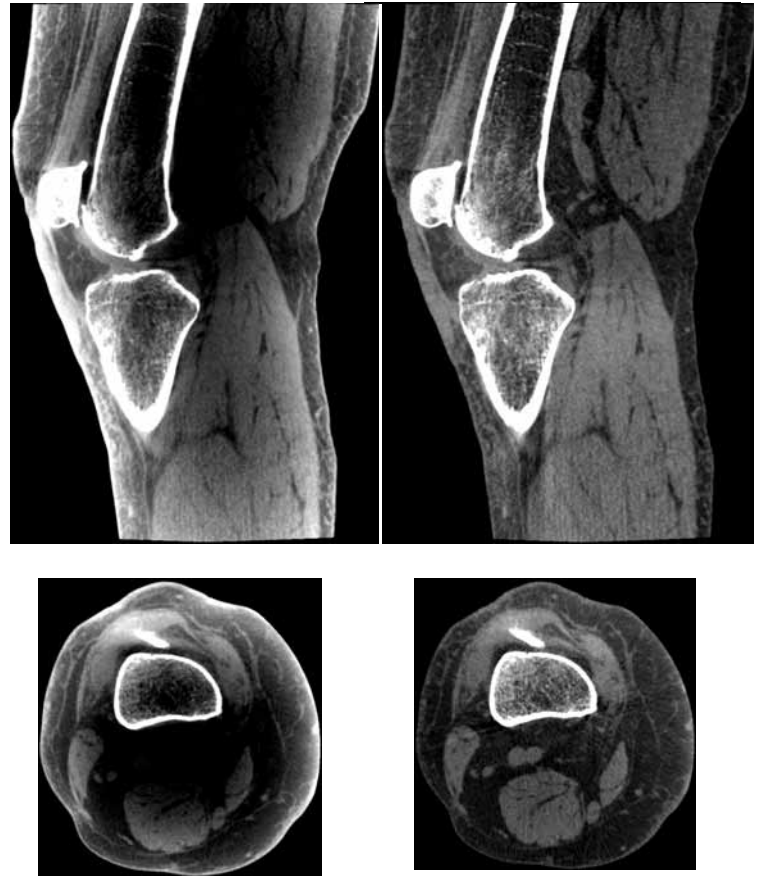
Figure 5 shows the patient, just prior to positioning through the open door into the scan volume (top image), and once the door has been closed (lower image). The patient positioning aids visible in the top image help to reduce patient motion during the scan.

Volume Reconstruction

To create a high-quality, reconstructed 3D volume from a cone beam system requires several corrections. Due to the increased volume that's imaged at one time, X-ray scatter plays a more significant role in CBCT than in traditional CT. The research system incorporated a scatter-correction approach designed to remove much of the scatter in the reconstructed volumes. (See Figure 6.)

Figure 6: Scatter correction

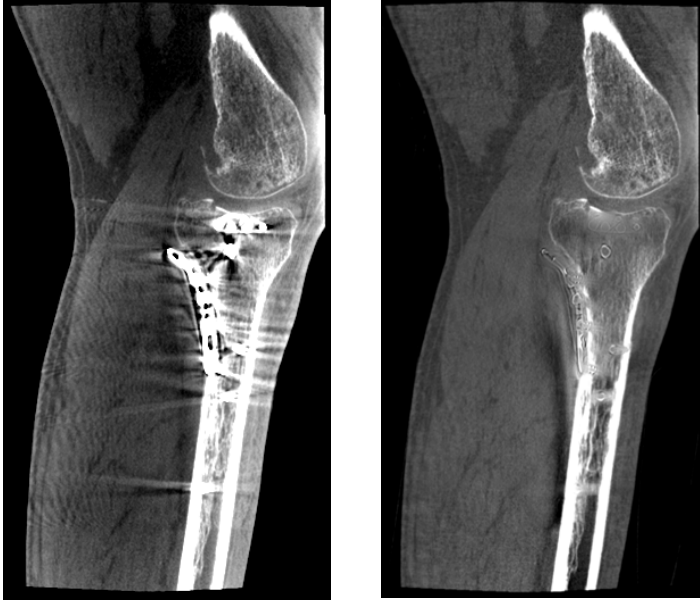

The prototyped scatter correction feature was designed to remove scatter from the reconstructed volumes.

White Paper | Cone Beam CT (CBCT) Imaging

As with traditional CT, the presence of highly attenuating objects, such as metal implants, can seriously compromise the reconstructed volume's clinical utility. The investigational system used a proprietary method for metal-artifact reduction (MAR) designed to improve the visibility of the patient's anatomy in the vicinity of metal components. (See Figure 7.)

Figure 7: Metal-artifact correction



This image demonstrates the effect that Carestream's research system's proprietary approach for metal-artifact reduction had on the visibility of patient anatomy around metal components.

To date, the most common method for volume reconstruction has been conventional filtered-back projection (FBP). This approach invariably requires several simplifying approximations to produce the reconstruction. These approximations can compromise the final image quality. More advanced reconstruction approaches, collectively known as iterative reconstructions, which use a different mathematical approach, are becoming more commonplace. When accurately corrected CBCT data are coupled with state-of-the-art reconstruction capabilities, the resulting images often display image quality that exceeds what is typically achievable with the CT acquisition protocols and reconstructions widely used today in the medical imaging community^{2,4}.

See Figure 8 for an example of the CBCT image quality resulting from a weight-bearing knee scan. The figure shows both the bone and soft tissue images captured with the Carestream CBCT research system during the investigational studies.

Figure 8: Bone and soft tissue capabilities of CBCT

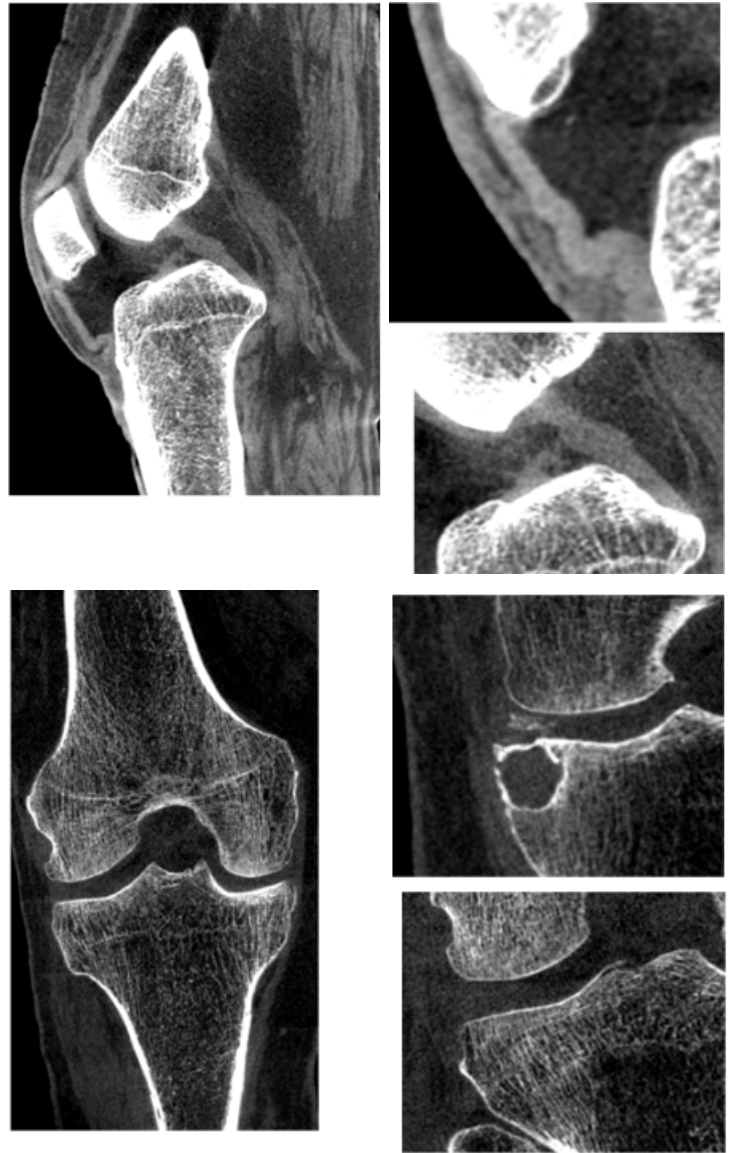

Figure 8 shows both bone and soft tissue images obtained with the Carestream CBCT research system.

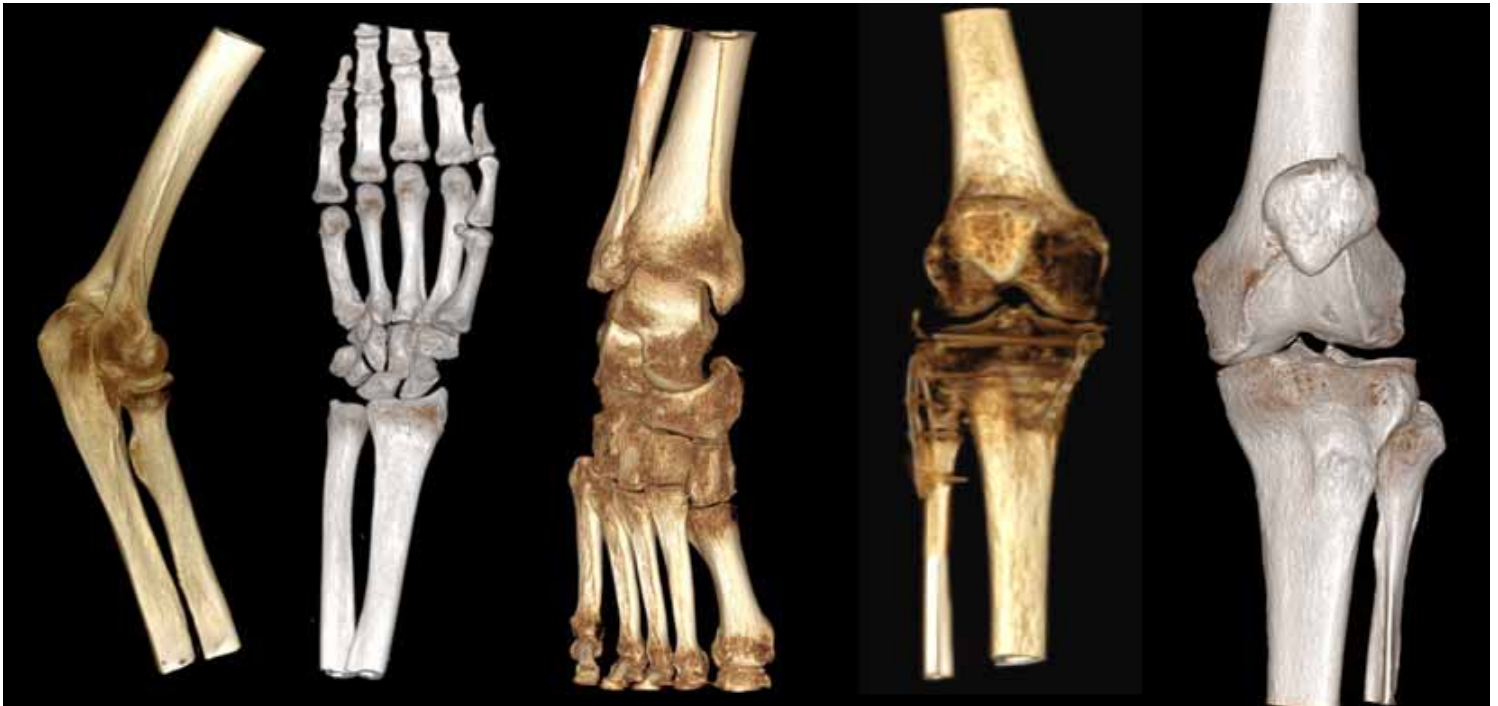White Paper | Cone Beam CT (CBCT) Imaging

Conclusion

The advent of CBCT imaging systems designed to address the unique issues of different clinical specialties presents a high-value promise. These systems can extend the use of high-quality three-dimensional imaging to a much wider audience than previously served by traditional CT. Volumetric imaging in nontraditional locations will require the combination of small physical size, optimized patient workflow, weight-bearing imaging and state-of-the-art reconstruction with advanced scatter and metal correction features – making CBCT a well-suited system for Point of Care.

Carestream Health has a long history in the field of volumetric cone beam imaging and is bringing this expertise to the field of orthopaedic extremity imaging. Carestream, through its research and investigational studies, continues to develop novel features and functionality specific to 3D extremity imaging in orthopaedic offices, trauma centers and sports medicine clinics, in addition to hospital-based radiology and emergency departments. Figure 9 demonstrates a selection of surface-rendered images from Carestream research systems, which shows the range of anatomy that this new research system is capable of imaging.

Figure 9: 3D surface-rendered images



References

- (1) Zbijewski. et.al. "Dual-energy Imaging of Bone Marrow Edema on a Dedicated Multi-Source Cone-Beam CT System for the Extremities," SPIE Physics of Medical Imaging (2015) 94120V-1 to 6
- (2) Carrino et.al. "Dedicated Cone-Beam CT System for Extremity Imaging," Radiology (2013) 270(3) 816-824
- (3) Koivisto et.al. "Assessment of Effective Radiation Dose of an Extremity CBCT, MSCT and Conventional X-ray for Knee Area Using MOSFET Dosimeters," Radiat. Prot. Dosim. (2013) 157(4) 515-524
- (4) Demehri et.al. "Assessment of Image Quality in Soft Tissue and Bone Visualization Tasks for a Dedicated Extremity Cone-beam CT System," European Radiology (2015) 25(6) 1742-1751